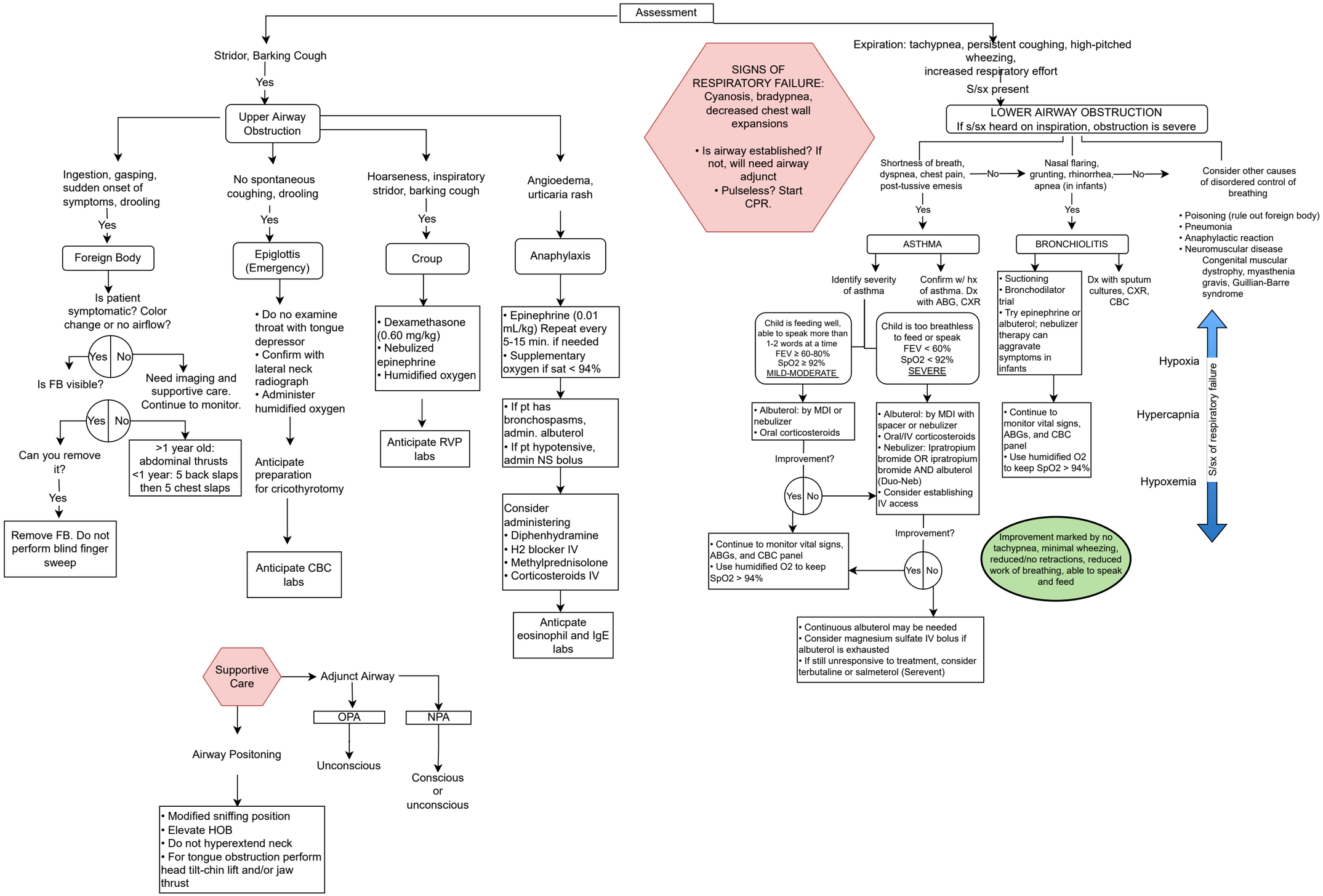
Assessment
Stridor, Barking Cough
Yes
Upper Airway Obstruction
Ingestion, gasping, sudden onset of symptoms, drooling
Yes
Foreign Body
Is patient symptomatic? Color change or no airflow?
Yes
No
Is FB visible?
Need imaging and supportive care. Continue to monitor.
Yes
No
Can you remove it?
>1 year old: abdominal thrusts
<1 year: 5 back slaps then 5 chest slaps
Yes
Remove FB. Do not perform blind finger sweep
No spontaneous coughing, drooling
Yes
Epiglottis (Emergency)
• Do no examine throat with tongue depressor
• Confirm with lateral neck radiograph
• Administer humidified oxygen
Anticipate preparation for cricothyrotomy
Anticipate CBC labs
Hoarseness, inspiratory stridor, barking cough
Yes
Croup
• Dexamethasone (0.60 mg/kg)
• Nebulized epinephrine
• Humidified oxygen
Anticipate RVP labs
Angioedema, urticaria rash
Anaphylaxis
• Epinephrine (0.01 mL/kg) Repeat every 5-15 min. if needed
• Supplementary oxygen if sat < 94%
• If pt has bronchospasms, admin. albuterol
• If pt hypotensive, admin NS bolus
Consider administering
• Diphenhydramine
• H2 blocker IV
• Methylprednisolone
• Corticosteroids IV
Anticpate eosinophil and IgE labs
SIGNS OF RESPIRATORY FAILURE: Cyanosis, bradypnea, decreased chest wall expansions
• Is airway established? If not, will need airway adjunct
• Pulseless? Start CPR.
Supportive Care
Airway Positoning
• Modified sniffing position
• Elevate HOB
• Do not hyperextend neck
• For tongue obstruction perform head tilt-chin lift and/or jaw thrust
Adjunct Airway
OPA
Unconscious
NPA
Conscious or unconscious
Expiration: tachypnea, persistent coughing, high-pitched wheezing, increased respiratory effort
S/sx present
LOWER AIRWAY OBSTRUCTION
If s/sx heard on inspiration, obstruction is severe
Shortness of breath, dyspnea, chest pain, post-tussive emesis
No
Nasal flaring, grunting, rhinorrhea, apnea (in infants)
No
Consider other causes of disordered control of breathing
• Poisoning (rule out foreign body)
• Pneumonia
• Anaphylactic reaction
• Neuromuscular disease
Congenital muscular dystrophy, myasthenia gravis, Guillian-Barre syndrome
Yes
ASTHMA
Identify severity of asthma
Confirm w/ hx of asthma. Dx with ABG, CXR
Child is feeding well, able to speak more than 1-2 words at a time
FEV ≥ 60-80%
SpO2 ≥ 92%
MILD-MODERATE
Child is too breathless to feed or speak
FEV < 60%
SpO2 < 92%
SEVERE
• Albuterol: by MDI or nebulizer
• Oral corticosteroids
Improvement?
Yes
No
• Albuterol: by MDI with spacer or nebulizer
• Oral/IV corticosteroids
• Nebulizer: Ipratropium bromide OR ipratropium bromide AND albuterol (Duo-Neb)
• Consider establishing IV access
Improvement?
Yes
No
• Continue to monitor vital signs, ABGs, and CBC panel
• Use humidified O2 to keep SpO2 > 94%
• Continuous albuterol may be needed
• Consider magnesium sulfate IV bolus if albuterol is exhausted
• If still unresponsive to treatment, consider terbutaline or salmeterol (Serevent)
Yes
BRONCHIOLITIS
• Suctioning
• Bronchodilator trial
• Try epinephrine or albuterol; nebulizer therapy can aggravate symptoms in infants
Dx with sputum cultures, CXR, CBC
• Continue to monitor vital signs, ABGs, and CBC panel
• Use humidified O2 to keep SpO2 > 94%
Improvement marked by no tachypnea, minimal wheezing, reduced/no retractions, reduced work of breathing, able to speak and feed
Hypoxia
Hypercapnia
Hypoxemia
S/sx of respiratory failure